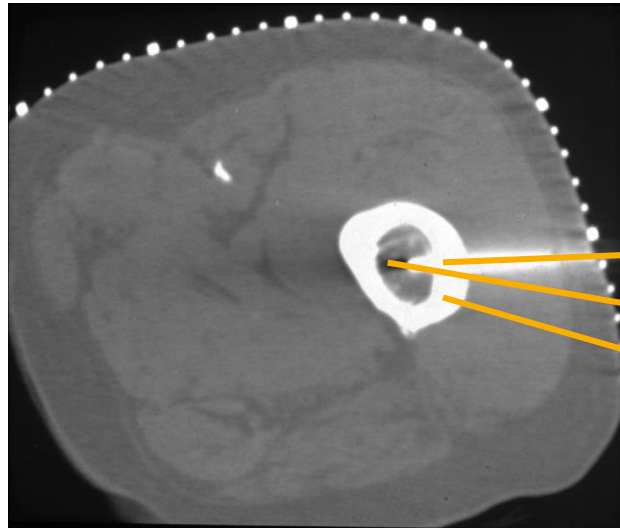


Penetration of 8 mm cortical bone

Procedural Information

Location: Uppsala, Sweden
Hospital: Uppsala University Hospital
Physician: Dr K. Gunnar O. Åström
Dr K. Håkan Ahlström



Case Description

Case history

Seventy-five year old man with a suspected metastasis in the femoral shaft.

Biopsy details

Penetration of the 8mm thick, cortical bone was achieved by manually drilling with the Bonopty® Drill. The drill was then exchanged for the Bonopty® Biopsy Cannula which was used to obtain two samples in the bone marrow, through the anchored Bonopty® Penetration Cannula.

Analysis of the samples

Histologic examination of these samples revealed metastatic bone marrow involvement.

Comments

The intact, thick cortical bone was easily penetrated with the eccentric drill using only finger-tip force.

CT scan of the femur

- The anchored Bonopty® Penetration Cannula
- Samples obtained with the Bonopty® Biopsy Cannula
- 8 mm thick cortical bone

Case and image courtesy of Dr K. Gunnar O. Åström and Dr K. Håkan Ahlström, Uppsala University Hospital.